

Pathological findings of myocardium in carbon monoxide poisoning are basically similar to those in hypothermic deaths.

Satomu Morita, Satoshi Furukawa*, Lisa Wingefeld**, Katsuji Nishi,

Department of Legal Medicine, Shiga University of Medical Science

*: Corresponding Author

** : Institut fuer Rechtsmedizin, Ludwig-Maxilians Universitaet Muenchen

home > Vol.14, No. 2, July - December 2013 > Paper 12 by Satomu Morita and colleagues (you are here)

Navigation ribbon

Received: June 14, 2013

Reviewers comments received: June 26, 2013

Accepted: June 26, 2013

First published online as Epubahead: June 26, 2013

Ref: ● Morita S, Furukawa S, Wingefeld L, Nishi K. Pathological findings of myocardium in carbon monoxide poisoning are basically similar to those in hypothermic deaths. *Anil Aggrawal's Internet Journal of Forensic Medicine and Toxicology* [serial online], 2013; Vol. 14, No. 2 (July - December 2013): [about 8 p]. Available from:

http://www.anilaggrawal.com/ij/vol_014_no_002/papers/paper012.html. Published : July 1, 2013, (Accessed: August 16, 2013)

✉ Email Dr Satoshi Furukawa by [clicking here](#)



Satomu Morita

Pathological findings of myocardium in carbon monoxide poisoning are basically similar to those in hypothermic deaths

by

Satomu Morita, Satoshi Furukawa*, Lisa Wingefeld**, Katsuji Nishi,
Department of Legal Medicine, Shiga University of Medical Science

*: Corresponding Author

** : Institut fuer Rechtsmedizin, Ludwig-Maxilians Universitaet Muenchen

[Click here](#) to download paper

[Click here](#) to download table and figures associated with this paper

● N.B. It is essential to read this journal - and especially this paper as it contains several tables and high resolution graphics - under a screen resolution of 1600 x 1200 dpi or more, and preferably on a 17" or bigger monitor. If the resolution is less than this, you may see broken or overlapping tables/graphics, graphics overlying text or other anomalies. It is strongly advised to switch over to this resolution to read this journal - and especially this paper. These pages are viewed best in Netscape Navigator 4.7 and above.

-Anil Aggrawal

● Click [here](#) to contact us.

● This page has been constructed and maintained by Dr. Anil Aggrawal, Professor of Forensic Medicine, at the Maulana Azad Medical College, New Delhi-110002. You may want to give me the feedback to make this pages better. Please be kind enough to write your comments in the guestbook maintained above. These comments would help me make these pages better.

● **IMPORTANT NOTE: ALL PAPERS APPEARING IN THIS ONLINE JOURNAL ARE COPYRIGHTED BY "ANIL AGGRAWAL'S INTERNET JOURNAL OF FORENSIC MEDICINE AND TOXICOLOGY" AND MAY NOT BE REPOSTED, REPRINTED OR OTHERWISE USED IN ANY MANNER WITHOUT THE WRITTEN PERMISSION OF THE WEBMASTER**

Abstract

It has been described that the myocardium did not show any ischemic types of changes or other lesions in human hearts obtained from fatal carbon monoxide poisoning cases, although some report indicated the existence of pathological changes in the myocardium from carbon monoxide poisoning cases. We investigated the changes in myocardium obtained from several individuals who died in suicidal carbon monoxide poisoning, in house fire cases and in suicidal burning with kerosene using conventional staining. And we compared the results with those obtained from individual who died due to hypothermia. With conventional staining the cardiac cells from both group showed color-changing with HE (eosinophilic color changing) and Azan (orange color changing) stains, colliquative myocytolysis and contraction bands necrosis, respectively, however aggregated cardiac cells was find only in those from hypothermic death. The results obtained in this study and together with previous one indicate that death mechanism of carbon monoxide poisoning and hypothermic resemble to each other, that is, cardiac hypoxia is surely caused by disturbance of oxygen releasing from hemoglobin in hypothermia and by lacking of oxygen due to high affinity of carbon-monoxide to hemoglobin in CO poisoning, respectively.

Key Words:

Carbon monoxide poisoning, Contraction band necrosis, Hypoxic myocardium

Introduction

When the myocardial cells arrest in contraction state, the hyper-contracted myocardial cells break down forming hyper-eosinophilic transverse bands constituted by hyper-contracted, extremely short sarcomeres with highly thickened Z line with Hematoxylin-Eosin Stain (HE stain) ⁽¹⁾. It has been reported that the contraction band necrosis (CB) has been associated with coronary occlusion, resuscitation attempt, drowning, intracranial hemorrhage, sudden cardiac death and a wide variety of drugs ⁽²⁾.

In a previous study ^(3,4), we investigated the histological characteristics of the heart obtained from hypothermic death individuals and showed that 4 kinds of histological findings were detected, that is, 1) The cardiac cells remarkably closed adherence to each other, 2). The number of red or orange colored cardiac cells (colored cell) by HE or Azan stain, respectively, was frequent than that of control. 3). The cardiac cells with severe vacuolar, colliquative myocytolysis (CM), were identified in the papillary and left ventricle muscles. 4) The contraction bands (CB) in the cardiac cells were recognized mainly in sections from the septum of the hearts obtained from hypothermic and coldwater immersion death by Azan staining, which was more effective to detect the bands than that by HE stain. And we indicated that the hypothermic death might mainly be caused by hypoxia due to decreasing of oxygen dissociation from hemoglobin. In our routine postmortem examination we often observed existence of contraction band necrosis in burned bodies with various saturation level of carbon monoxide hemoglobin (COHb). These experiences conduct us to investigate the validity of Azan stain to detect the contraction bands in the myocardium obtained from charred bodies and/or carbon monoxide death individuals, although the existence of the contraction band necrosis has not been described in the cardiac tissue obtained from fatal carbon monoxide poisoning ^(5,6). Additionally it is well known that

carbon monoxide binds to the myoglobin⁽⁷⁾ and cytochrome oxidase⁽⁸⁾. Carbon monoxide has a high affinity for hemoglobin and myoglobin, about 200 times greater than those of oxygen, respectively, and cause reduces cardiac output and hypotension. The binding of carbon monoxide to cytochrome oxidase also interferes with aerobic metabolism and efficient ATP synthesis. These situations seem to be the similar to that in hypothermic death, since lacking of oxygen or decreasing of oxygen releasing results decreasing ATP producing in the tissue. In this study we examined whether the existence of CB, orange changed myocardial cells and CM in the myocardium from bodies with high level of COHb are detectable by HE or Azan stains.

Materials and Methods

We have performed routinely histological examination in four parts of the hearts, that is, the horizontal sections from right and left ventricle and septum and the longitudinal sections of the interventricular septum including conduction system by HE and Azan stain. In a preliminary study, we observed a large number of the contraction band necrosis in the myocardium obtained from 74 year-old male who died in a suicidal house fire, however the complete obstruction of coronary artery and severe thermal damage were detected in his myocardium, as shown in Figure 1., since we selected the specimens from individuals without coronary-sclerosis, heart diseases and severe thermal changes on the cardiac surface in this study.

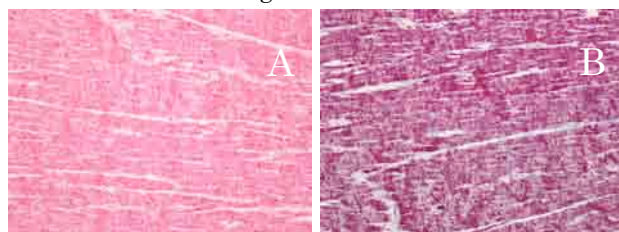


Figure 1. Contraction band detected in a 74 year old male who died due to suicidal house burning with severe thermal damage in the heart.

A large number of contraction band were detected by HE stain (A), and in the Azan Staining (B) the color was not different from that from other individuals.

We selected 20 individuals who died due to carbon monoxide poisoning. The age, gender, cause of death, saturation level of COHb, and death scene situation were described in Table 1. In one case unrelated 5 persons died in a car, and in two family cases 5 persons died in independent cars. One person, and two pairs of lovers and male co-workers died in their own houses. All died using burning charcoal briquette. We additionally selected 5 persons with/without COHb, who found in house fire or died due to suicidal fire. All died without resuscitation attempts of any type. The results obtained from each individual were compared with those of hypothermic death cases in previous report⁽³⁾.

Table 1. Summary of individuals examined and staining results

No.	Age	Sex	COHb(%)	cause of death	Orange	Colliquate	Contraction B				Postmortem Interval	Remaining CO ₂ %
							S-L	S-T	L	R		
A-1	10	F	73.3	CO: charcoal	+	+	+	-	-	-	36hours	ND
A-2	14	F	73.7	CO: charcoal	+	+	+	+	-	-	30hours	ND
A-3	43	M	72.5	CO: charcoal	+	+	+	+	-	-	33hours	ND
A-4	9	F	70	CO: charcoal	+	+	+	+	-	-	2.5days	ND
A-5	43	F	74.2	CO: charcoal	+	+	-	-	-	-	2.5days	ND
A-6	40	M	66.5	CO: charcoal	+	+	+	+	-	-	2.5days	ND
A-7	25	M	72.8	CO: charcoal	+	+	+	+	-	-	2.5days	ND
A-8	27	F	74.2	CO: charcoal	+	+	+	+	-	-	2.5days	ND
A-9	28	M	71.3	CO: charcoal	+	+	+	+	-	-	2.5days	ND
A-10	19	F	79.7	CO: charcoal	+	+	+	+	-	-	2.5days	ND
A-11	43	F	66.5	CO: charcoal	+	+	+	+	-	-	3.5days	ND
A-12	39	M	93.7	CO: charcoal	+	+	+	+	-	-	25hours	29.7
A-13	41	F	82.8	CO: charcoal	+	+	+	+	-	-	25hours	27.7
A-14	46	M	78.4	CO: charcoal	+	+	-	+	-	-	4days	29.7
A-15	40	M	80	CO: charcoal	+	+	-	+	-	-	7days	32.7
A-16	38	M	78.5	CO: charcoal	+	+	-	+	-	-	7days	21.4
A-17	26	M	87.1	CO: charcoal	+	+	-	+	-	-	6days	24.3
A-18	25	F	81.6	CO: charcoal	+	+	-	+	-	-	6days	26.8
A-19	55	M	84.1	CO: charcoal	+	+	-	+	-	-	3days	22.8
A-20	57	F	79.4	CO: charcoal	+	+	-	+	-	-	3days	33.7
B-1	43	F	79.5	house fire	+	+	+	+	+	+	30hours	45.7
B-2	13	F	89.5	house fire	+	+	+	+	+	+	30hours	44.2
B-3	16	F	83.5	house fire	+	+	+	+	+	+	30hours	51.7
C-1	62	F	0	fire: suicide	+	+	+	+	+	+	30hours	46
C-3	59	M	0	fire: suicide	+	+	+	+	+	+	24hours	65
D-1	26	F	0	hypothermia	+	+	+	+	+	+	30hours	56.3

CO: saturation of COHb, CO:charcol; suicidal CO poisoning, Orange: color changed cells; Colliquate; cells with vacuoles, contraction B; contraction band, R; right ventricle, S-L, S-T; septum longitudinal or transverse, L; left ventricle, GC; granular cells in the cerebellum; ND; not determined

Determination of COHb in blood from each individual was performed by visible spectrophotometry method⁽⁹⁾.

We additionally tried to evaluate the agonal duration of 14 individuals who died due to carbon monoxide poisoning within last two years. We calculated the remaining of granular cells in the cerebellum according to our previous study⁽¹⁰⁾. The evaluation of alteration of the granular cells

was performed using Photoshop™ application. After taking photograph of the GCL stained by HE at microscopy level using Nikon H550S™ system at magnification ×400. Color of nucleuses of the granular cells was changed into gray and then the ratio of the number of pixels with gray color and other color was counted with Adobe Photoshop CS5™ (Adobe Systems™). The frequency of the remaining cells was indicated as percentage of the total number of pixel with gray color in the GCL. The area of remaining granular cells was indicated as the percentage of the GCL. When we counted number of pixels, we chose five visual fields of GCL which looked equable and calculated average. In every case, whole pixels of one fields was 327,680 pixels.

Results

The colored cells by HE or Azan stain were detected in the myocardium both from all of suicidal CO poisoning and death in house fire cases. The CMs were also observed specially in endocardium sides in all case examined. The close adherence of the cardiac cells was not detected in CO poisoning cases. The CB were detected mainly in the right ventricle from 18 cases of suicidal CO poisoning and not detected in 2 cases of suicidal CO poisoning. However the CB were detected in right ventricle and/or longitudinal sections of the inter-ventricular septum from all case in

accidental house fire, irrespectively the level of COHb, although the frequency of CB expression was remarkable in individuals with low level of COHb and thermal changes on the chest wall. Typical findings obtained from an individual who died in a bedroom with her lover using burning charcoal briquette were shown in Figure 2. The hypoxic changes detected by conventional stains seemed to be weaker than those in

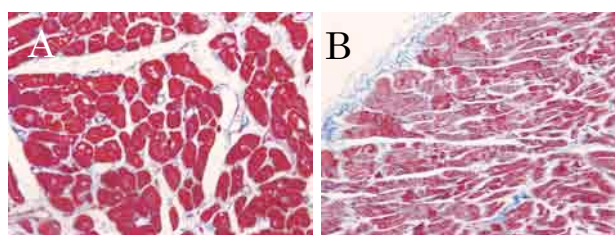


Figure 2. Hypoxic changes observed in the myocardium using Azan stain.

Azan stain showed orange color myocardial cells in the left ventricle (A) and contraction bands and colliquative myocytolysis (B) were also recognized in the right ventricle obtained from A-13 case who died carbon monoxide poisoning using burning charcoal briquet.

hypothermic death. ⁽³⁾. There was no bleeding and leukocyte infiltration in the myocardium were detected in this study. The summary of staining results obtained from each individual was listed in Table 1. The results obtained from CO poisoning resemble to those from hypothermic death, however the intensity and frequency of findings were clearly and intensity in hypothermic death. Characteristics findings in hypothermic death were shown in Figure 3.

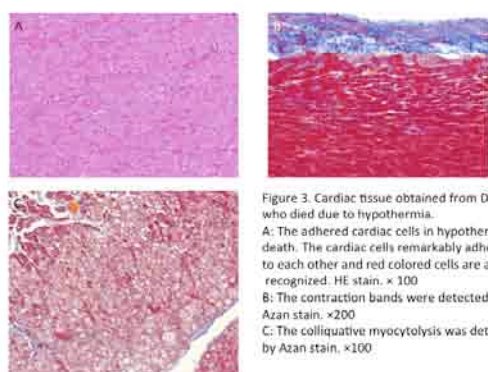


Figure 3. Cardiac tissue obtained from D-1 case who died due to hypothermia.
A: The adhered cardiac cells in hypothermic death. The cardiac cells remarkably adhered to each other and red colored cells are also recognized. HE stain. ×100
B: The contraction bands were detected by Azan stain. ×200
C: The colliquative myocytolysis was detected by Azan stain. ×100.

The results of calculation of remaining the granular cells in the cerebellum were described in Table 1, and showed that the remaining granular cells were higher in suicidal burning, middle in house fire and lower in suicidal CO intoxication. The remaining of the granular cells in the cerebellum obtained from D-1 case who died due to hypothermia on a road was higher level compared with those in individuals died in house fire.

Discussion

CO poisoning is known to cause myocardial toxicity and life threatening arrhythmias and COHb level correlated with prolonging of QT intervals and releasing of cardiac enzymes ⁽¹¹⁾. On the contrary Fineschi et al ⁽⁴⁾ described that the myocardium did not show any ischemic types of changes or other lesions in human hearts obtained from fatal carbon monoxide poisoning cases. These reports allow us to make an examination whether hypoxic changes are able to observe in the myocardium from CO related deaths.

The colored cell stained by Azan and HE was obviously observed in all section examined. It was showed that these colored cells by both stains were completely corresponding to each other in our previous report concerning hypothermic deaths ⁽³⁾. The cells with CM were also detected in all specimen examined. These results indicate that hypoxic changes surely occur in the heart in carbon monoxide poisoning, confirming the results reported by Fracasso et al ⁽¹²⁾. This study could also show the existence of CB in the cardiac cells from almost all of individual in house fire and even in cases of suicidal carbon monoxide poisoning. However the pathological changes including CB, CM and colored cells, were intensively and clearly in the hypothermic death compared with those in CO related death. Although the whole heart and body may be affected in both of hypothermic and CO related death, the progress and duration of ischemic/hypoxic condition between two situations may be different, that is, moderately occurring in the CO poisoning and relatively slowly in the hypothermia. The number of remaining granular cells was higher in suicidal burning, middle in house fire and lower in suicidal CO intoxication. This result may indicate that the difference of remaining may be caused by agonal duration. The remaining of the granular cells in the cerebellum obtained from D-1 case who died due to hypothermia on a road was higher level. It seems that hypothermic situation prevent the progressing of cell damage during agonal duration.

In this study we found CB and ischemic types of changes mainly in the right ventricles and longitudinal section of myocardial septum. Fracasso et al ⁽¹²⁾ also reported that fresh cardiac damage was detected with the antibody fibronectin in cases of CO poisoning and was prevalently localized at the right ventricle. Fineschi et al ⁽⁴⁾ examined, however, only 2-4 samples obtained from the anterior wall of the left ventricle, although they described no ischemic/hypoxic changes in the myocardium in CO poisoning cases. The present study may indicate that the right ventricle and longitudinal section of myocardial septum presumed to be useful for detecting CB. Staining intensity of CB was clearer in Azan stain than that by HE stain in this study.

Since one of several causes presumed in hypothermic death was surely the hypoxic situation resulted from decreasing of oxygen dissociation from hemoglobin, the existence of high level of COHb in carbon monoxide poisoning cases also seems to bring out hypoxic changes in the myocardium. However we should deliberate on the materials included in the myocardial cells, that is, myoglobin, creatine, and cytochrome c oxidase, and some other toxic gasses expressed in house fire cases also may have cardiac toxicity.

It is well known that abundant myoglobin and creatine pools exist in cardiac tissue, and their roles have been extensively studied ⁽¹³⁾. Myoglobin may work as an oxygen buffer, facilitate oxygen diffusion at low cellular oxygen tension ⁽¹⁴⁾ and/or catalyze chemical reactions, such as NO scavenging ⁽¹⁵⁾. Similarly, the creatine kinase system may either buffer cellular ATP levels or

facilitate ATP diffusion inside myocytes⁽¹⁶⁾. Wu and Beard⁽¹⁷⁾ described that myoglobin has little impact on cardiac energetics, while the creatinine kinase (CK) system is important for the beating heart to maintain stable energetic state over a range of cardiac work rate and the CK system stabilizes D-GATPase by both buffering ATP and ADP concentrations and enhancing the feedback signal of inorganic phosphate in regulating mitochondrial oxidative phosphorylation. Hendgen-Cotta et al⁽¹⁸⁾ reported that the heme globins such as myoglobin, hemoglobin, neuroglobin, and cytoglobin, subserve a critical function as nitrite reductases that regulate hypoxic NO[•] signaling in hypoxic myocardium.

Several kinds of toxic gasses such as HCN and NO_x were produced in house fires⁽¹⁹⁾. Both of HCN and CO combines hemoglobin, myoglobin and cytochrome-c oxidase, and bring out the decreasing of oxygen supply in the peripheral tissue and reduction of ATP producing in the mitochondria of the cardiac cells. In the hypothermic status the decreasing oxygen supply and reduction of producing ATP was also expected. The mechanism of reduction of ATP and hypoxic signaling⁽²⁰⁾ in the cardiac tissues are similar to the situation of hypothermic death, the difference was presumed in the affecting time between the agony times in hypothermia and CO poisoning.

A large amount of CB existing in the myocardium obtained from victims from house fire and suicidal burning cases might be result of heating damage on the heart tissue, since Turek et al⁽²¹⁾ described that microwave energy caused acute coagulation necrosis with hypereosinophilic myocytes with both nuclear loss and pyknosis and severe contraction bands. The CB detected in victims with thermal damage is presumed to show some difference characteristics, since the CB were stained into purplish orange, and the CB from high level of COHb showed clear orange color.

Conclusion

Hypoxic pathological changes such as cells with eosinophilic or orange color, CM and CB, were detected even in carbon monoxide poisoning cases just like those in hypothermic deaths, however closed cell adherence that presumed specific finding in hypothermic death was not observed. Forensic pathologists should examine many part of the heart, especially longitudinal tissue section of intraventricular septum.

References

- 1). Baroldi G, Bigi R, Cortigiani L, Ultrasound imaging versus morphopathology in cardiovascular disease. Myocardial cell damage. Cardiovasc Ultrasound 2005; 3: 32 doi:10.1186/1476-7120-3-32. PMID: 16209715
- 2). Baroldi G, Mittleman R E, Parolini M, Silver MD, Fineschi V. Myocardial contraction bands, Definition, quantification and significance in forensic pathology. Int J Legal Med, 2001; 115: 142- 151. PMID: 11775016
- 3). Furukawa S, Wingenfeld L, Takaya A, Nakagawa T, Sakaguchi I, Morita S, Yamasaki S, Nishi K. Histopathological characteristics of human cardiac tissues in accidental hypothermia using conventional staining techniques. Rom J Leg Med.2012; 20: 241-246. <http://www.rjlm.ro/?doc=1340793172>
- 4). Furukawa S, Wingenfeld L, Sakaguchi I, Nakagawa T, Takaya A, Morita S, Yamasaki S, Nishi K, Histtopathological characteristic of human cardiac tissues in accidental hypothermia using immunohistochemistry: Immunohistochemical detections of cold, hypoxia and apoptotic related antigens are practicable in the myocardium from hypothermic death even in postmortem examination. Anil Aggrawal's Internet Journal of Forensic Medicine and Toxicology, 2013; 14, http://www.anilaggrawal.com/ij/vol_014_no_001/papers/paper004.html

- 5). Fineschi V, Agricola E, Barrodi C, Bruni G, Cerretani D, Mondillo S, Parolini M, Turillazi E, Myocardial findings in fatal carbon monoxide poisoning: a human and experimental morphometric study, *Int J Legal Med* 2000; 113: 276-282. PMID: 11009063
- 6). Kumazawa T, Watanabe-Suzuki K, Seno H, Ishi A, Suzuki O, A curious autopsy case of accidental carbon monoxide poisoning in a motor vehicle, *Legal Med* 2000; 2: 181-185. PMID: 12935724
- 7). Nelson LH, "Carbon Monoxide". Goldfrank's toxicologic emergencies (7th ed.). New York: McGraw-Hill. pp. 1689-1704. 2002
- 8). Gorman D F, Runciman W B, Carbon monoxide poisoning, *Anesthesia and Intensive Care* 1991; 19: 506- 511. <http://www.aaic.net.au/Document/?D=1091097>
- 9). Katsumata Y, Aoki M, Sato K, Suzuki O, Oya M, Yada S, A simple spectrophotometry for determination of carboxyl-hemoglobin in blood, *J Forensic Sci.* 1982; 27: 928-934. PMID: 7175473
- 10). Morita S, Furukawa S, Takaya A, Sakaguchi I, Okunaga H, Nakagawa T, Wingenfeld L, Nishi K, Usability of histological assessment of cerebellar granule cell layer regardless of postmortem interval. *J Forensic Research*, 2013; in preparing to open access.
- 11). Yelken B, Tanriverdi B, Cetinbas, Memis D, Suet N, The assessment of QT intervals in acute carbon monoxide poisoning, *Anadolu Kardiyol Derg* 2009; 9: 397-400. PMID: 19819791
- 12). Fracasso T, Pfeiffer H, Michaud K, Koehler H, Sauerland C, Schmelting A, Immunohistochemical expression of fibronectin and C5b-9 in the myocardium in cases of carbon monoxide poisoning. *Int J Legal Med*, 2011; 125: 377-384. PMID: 20848122
- 13). Jurgens K D, Papadopoulos S, Peters T, Gros G: Myoglobin: Just an Oxygen store or also an oxygen transporter? *News Physiol Sci* 2000; 15: 269-274. PMID: 11390925
- 14). Wyman J: Facilitated diffusion and the possible role of myoglobin as a transport mechanism. *J Biol Chem* 1966; 241: 115-121. PMID: 5901042
- 15). Rassaf T, Floegel U, Drexhage C, Hendgen-Cotta U, Kelm M, Schrader J: Nitrite reductase function of deoxymyoglobin: oxygen sensor and regulator of cardiac energetics and function. *Circ Res* 2007; 100:1749-1754. PMID: 17495223
- 16). Schlattner U, Tokarska-Schlattner M, Wallimann T: Mitochondrial creatine kinase in human health and disease. *Biochimica Et Biophysica Acta Molecular Basis of Disease* 2006; 1762:164-180. PMID: 16236486
- 17). Wu F, Beard D A, Roles of the creatine kinase system and myoglobin in maintaining energetic state in the working heart, *BMC Systems Biology* 2009, 3:22. doi:10.1186/1752-0509-3-22. PMID: 19228404
- 18). Hendgen-Cotta, Merx M W, Shiva S, Schmitz J, Becher S, Klare J P, Teinhoff H-J, Goedecke A, Schrader J, Gladwin M T, Kelm M, Rassaf T, Nitrite reductase activity of myoglobin regulates respiration and cellular viability in myocardial ischemic-reperfusion injury, *PNAS* 2008; 105: 10256-10261. PMID: 18632562
- 19). Morikawa T, Evolution of toxic gasses from burning polymereic materials in a small-scale box model. *Fire and Materials*, 1988; 12: 43-49. <http://onlinelibrary.wiley.com/doi/10.1002/fam.810120202/abstract>
- 20) Floegel U, Fago A, Rassaf T, Keeping the heart in balance: the functional interactions of myoglobin with nitrogen oxides, *J Experi. Biolo*, 2010; 213: 2726- 2733. PMID: 20675541
- 21). Turek JW, Dibernard L R, Lodge A J, Lin S S, Davis R D, Milano C a M, Sinsir S A, Histopathology and transmuralty of acute microwave lesion on the beating human atrium, *Interact Cardiovasc Thorac Surg*, 2006; 5: 202-206. PMID: 17670548